



RESENTING CLINICAL SIGNS

DATE History: Experienced labored breathing ~2 weeks ago. Radiographs showed possible pulmonary edema/pleural effusion, no cardiomegaly. Responded to furosemide 2 mg/kg BID. Repeat radiographs showed clearer lungs. No murmur. Inappetent. FeLV +.

3/31/22

ECHOCARDIOGRAPHIC FINDINGS

2D, M-mode, and Doppler study.

PERFORMED BY:

Dr. Meredith Swart

Left atrial size is normal. The mitral valve appears normal. Left ventricular wall thickness is normal. Left ventricular internal dimensions are normal. Left ventricular systolic function is hyperdynamic. The aorta and aortic valve appear normal. Right atrial and right ventricular dimensions are normal. The tricuspid valve appears normal. The pulmonary artery and pulmonic valve are normal. No shunting lesions are visualized. No pericardial effusion is seen.

INTERPRETED BY

Keith Blass, DVM,
MS, DACVIM
(Cardiology)

LA/Ao – 1.31
IVSd – 5.1 mm
LVPWd – 5.3 mm
LVIDd – 14.3 mm
LVIDs – 5.5 mm
FS – 61.5%
LVOT – 0.95 m/s
RVOT – 1.20 m/s

PATIENT

Sunshine Nazworth

SPECIES

Feline

ASSESSMENT/RECOMMENDATIONS

BREED

DSH

This examination demonstrates no obvious evidence of structural heart disease. While I haven't seen Sunshine's radiographs, the absence of abnormalities in this exam suggests that his previous labored breathing was not cardiogenic in origin, and if furosemide did result in improvement, it's likely that either non-cardiogenic edema or a disease that responded to the medication's anti-inflammatory property was present.

SEX

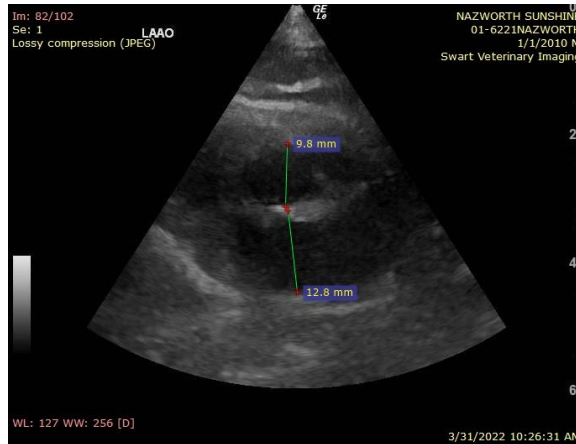
Furosemide can be continued given Sunshine's clinical improvement, however, no specific indication for its use is seen in his echocardiogram.

MN

A recheck echocardiogram is recommended if new physical exam and/or clinical abnormalities suggestive of cardiac dysfunction develop.

AGE

11 y



WEIGHT

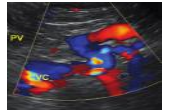
18.2 lb

HOSPITAL NAME

Swart Veterinary
Imaging

REFERRING VET

Dr. Swart



DATE

3/31/22

The information and recommendations provided are based on the images presented by the referring veterinarian. No evaluation can be communicated regarding pathology that was not visible in the image/video clips provided.

PERFORMED BY:

Thank you for this referral. If the clinical or image interpretation does not parallel your findings or if I can be of any further assistance please contact me.

Dr. Meredith Swart

INTERPRETED BY

Keith Blass, DVM, MS, DACVIM (Cardiology)
KeithBlass@gmail.com
631-804-5754

Keith Blass, DVM,
MS, DACVIM
(Cardiology)

PATIENT

Sunshine Nazworth

SPECIES

Feline

BREED

DSH

SEX

MN

AGE

11 y

WEIGHT

18.2 lb

HOSPITAL NAME

Swart Veterinary
Imaging

REFERRING VET

Dr. Swart